

Evaluation of How Anesthesia Affect Body Temperature in Sows Using Infrared Thermography

A.S. Leaflet R3267

Jennifer English, Undergraduate Researcher;
Anna Johnson, Associate Professor;
Kenneth Stalder, Professor,
Department of Animal Science;
Locke Karriker, Professor,
Swine Medicine Education Center; VDPAM
Iowa State University;
Monique Pairis-Garcia, Assistant Professor
Department of Animal Science,
The Ohio State University;
Caitlyn Bruns, DNA Swine Genetics,
Columbus NE

Summary

The objective of this experiment was to determine the relationship between rectal temperature and infrared temperature measured on the inner eye, center- and ear base of sows undergoing anesthesia. A total of six sows were used. Sows were anaesthetized using a combination of xylazine, tiletamine HCl and ketamine. Thermal images at the inner ear, ear center and ear base were taken at 10 minute intervals starting ten minutes' post-anesthetic induction until the sow was able to stand or reached 91.7° F body temperature. Rectal temperatures were measured using a digital thermometer. Rectal temperature Pearson correlations were determined among the inner eye, center and ear base with a significance level set at $P \leq 0.05$. Percent variation accounted for by these locations was calculated as the correlation coefficient (r) raised to the second power and multiplied by 100 ($r^2 \times 100$). There was a positive correlation between rectal and inner eye, ear center and base ($P \leq 0.03$). The lowest correlation was between the ear base and accounted for 9% of the sows' rectal temperature variation. The correlation was the greatest for the inner eye and accounted for 38% of the sow's rectal temperature variation. In conclusion, thermal images of the inner eye provided an effective and less invasive approach to rectal temperature for sows undergoing anesthesia.

Introduction

Sows represent a unique population in the swine herd, as disease and age can make anesthesia induction risky. According to the American Society of Anesthesiologists, age, weight, disease status, and anatomical variation contribute to a heightened anesthetic risk and can lead to prolonged recovery times and increased post-anesthetic complications. A major complication associated with

anesthesia in mature swine is increased risk to develop low body temperature. Hence, monitoring sow temperature is imperative in order to introduce strategies to mitigate low body temperature. The most common way to conduct this is through monitoring rectal temperature, but this can be invasive to the sow. Thermal imaging technologies show promise to accurately assess temperature and are also less invasive. However, there has been little validation on the relationship between rectal temperature and other anatomical locations on the sow using infrared thermography. Therefore, the objective of this experiment was to determine the relationship between rectal temperature and infrared temperature measured on the inner eye, center- and ear base of sows undergoing anesthesia.

Materials and Methods

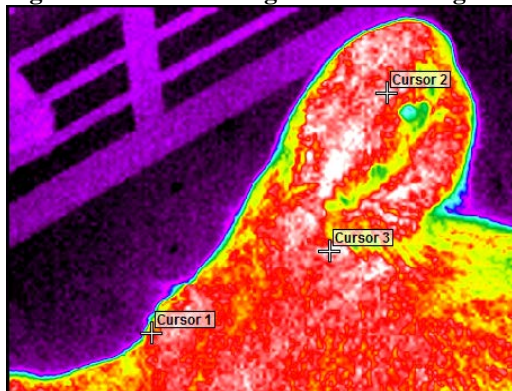
The protocol for this study was approved by the Iowa State University Animal Care and Use Committee.

Animals and housing: A total of six, multiparous, non-pregnant, cross-bred commercial maternal-line cull sows were used (mean bodyweight \pm standard deviation = 233.6 \pm 18.7 kg). All sows received a physical examination, which included lung and heart auscultation, rectal temperature, and reproductive tract ultrasonography. These sows were handled daily for research projects and were familiar with their environment and caretakers. The laboratory was located at Iowa State University, College of Veterinary Medicine, Ames, Iowa. To avoid confounding injury due to aggression, each sow was housed in an individual pen; however, sows could see, smell, hear, and have nose-to-nose contact with other cohorts. Sows were provided *ad libitum* access to water via one nipple drinker per pen. Sows were fed twice daily on a single feed bunk with a diet designed to meet or exceed nutrient requirements for gestating sows.

Anesthesia protocol: Sows were fasted overnight (16 hours), but were provided *ad libitum* access to water until 1 hour prior to anesthesia administration. Sows were restrained by a common pig snare in their home pen and anesthetized. Anesthetic agents were combined and injected at the doses indicated: xylazine (4.4 mg per kg); ketamine HCl (2.2 mg per kg); and tiletamine HCl and zolazepam HCl in combination (4.4 mg per kg). Anesthesia onset began once anesthetic agents were injected. Ten minutes after anesthesia onset, sows were placed in lateral recumbency. Posture was monitored to ensure involuntary movements did not result in compromised respiratory or circulatory capability for the sow.

Infrared: Thermal images (Wahl Multi-Purpose Thermal Imager HSI3000) of the inner eye, center and base of the ear (Figure 1) were taken at 10 minute intervals starting ten minutes' post-anesthetic induction until the sow was able to stand or reached 91.7° F body temperature. Rectal temperatures were measured using a digital thermometer. Inner eye, center of the ear, and base of the ear were interpreted using the Wahl HSI3000 Series Imager program.

Figure 1: Infrared image of the head region



Statistical analysis: Rectal temperature Pearson correlations were determined among the inner ear, center of the ear and base of the ear with a significance level set at $P \leq 0.05$. Percent variation accounted for by the three regions was calculated as the correlation coefficient (r) raised to the second power and multiplied by 100 ($r^2 \times 100$).

Results and Discussion

There was a positive correlation between rectal temperature and inner eye, center and base of the ear temperature ($P \leq 0.03$). The lowest correlation was between ear base and accounted for 9% of sows' rectal temperature variation. The correlation was the greatest for the ear center and accounted for 38% sow's rectal temperature variation (Table 1).

Table 1. Correlation coefficients (r) of sow rectal temperature when under anesthesia compared to inner eye and ear center and base

	Rectal
Rectal	1
Inner eye	$r = 0.53$ $r^2 = 28.09\%$ $P < 0.0001$
Center of the ear	$r = 0.62$ $r^2 = 38.44\%$ $P < 0.0001$
Base of the ear	$r = 0.30$ $r^2 = 9.00\%$ $P = 0.03$

In conclusion, thermal images of the inner eye provided an effective and less invasive approach to rectal temperature for sows undergoing anesthesia.

Acknowledgements

Thanks to Ms. Rebecca Parsons for sow care.