

Holt, E. (2018). Teaching tip: The use of MRI and ultrasound technology in teaching about Spanish (and general) phonetics and pronunciation. In J. Levis (Ed.), *Proceedings of the 9th Pronunciation in Second Language Learning and Teaching conference*, ISSN 2380-9566, University of Utah, September, 2017 (pp. 252-262). Ames, IA: Iowa State University.

TEACHING TIP:

THE USE OF MRI AND ULTRASOUND TECHNOLOGY IN TEACHING ABOUT SPANISH (AND GENERAL) PHONETICS AND PRONUNCIATION

D. Eric Holt, University of South Carolina

To teach pronunciation, it is useful for students to learn about articulatory phonetics, and to practice manipulating features of consonants and vowels. While diagrams are often presented to achieve this, these are static, and it is helpful to visualize movements of articulators via useful companions such as websites that involve functional MRI and ultrasound technology. One limitation of these is that they only present someone else's production. While fMRI is not currently a practical tool for classroom use, ultrasound technology may aid the student during the production of many potentially problematic speech sounds. In this teaching tip, an overview of online fMRI and ultrasound tools is given, with indications of their practical application.

INTRODUCTION

To teach pronunciation, it is useful for students to learn about articulatory phonetics, and this usually occurs in dedicated courses where pronunciation is embedded within the slightly larger context of phonetics and phonology. Students in these courses are instructed in the basics of the International Phonetics Association chart and symbols for transcription for both consonants (place and manner of articulation, voicing) and vowels (tongue height, backness, lip rounding, tenseness), and they usually practice identifying and manipulating these features. Often, diagrams are provided or presented to visualize these abstract characteristics. However, these are static, and being able to visualize movements of articulators can be very helpful to proprioception and development. To this end, useful companions that involve functional MRI and ultrasound technology may be employed, such as the websites “real-time MRI IPA charts”, “eNunciate!” and “Seeing Speech: IPA Charts.”

While these real-time anatomically-explicit views can be highly illuminating, they have the significant limitation that they only present someone else's production. fMRI is not currently a practical tool for classroom or language lab use, but ultrasound technology is lightweight, portable and relatively affordable, and can be used in the classroom in either group or individual settings. Students can directly see the position of their own tongue during the production of many speech sounds, and the real-time ultrasound images allow them to visualize themselves articulating sounds in new places and aid them to avoid pitfalls of tense/lax in vowels, clear vs. dark /l/, proper placement of palatals, and problematic sequences of sounds.

In this teaching tip, an overview of online fMRI and US tools is given, with indications of their practical application. On site, participants were given a live demonstration of ultrasound and afforded practice using the Interson 7.5MHz USB-laptop-connected wand.

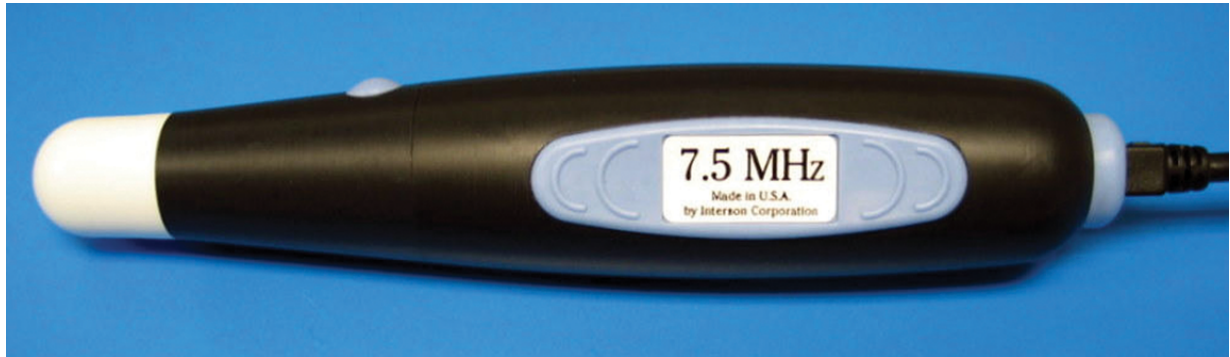

Figure 1. SeeMore Interson 7.5MHz USB-laptop-connected wand.

SEGMENTS HELPFUL TO VIEW WITH IMAGING

Below is a non-exhaustive list of segments, segment types and sequences for which it is especially useful to learners to visualize the production of speech, either via recorded fMRI or ultrasound, and to then visualize their own production using ultrasound. During the actual conference session, a sampling of these was demonstrated and practiced at the conclusion of the tip.

- tense vs. lax vowels: [ɛ] vs. [e]; [ɔ] vs. [o]; [ɪ] vs. [i]; [ʊ] vs. [u]
- diphthongized vs. simple vowels (diphthongs vs. monophthongs)
- tap vs. trill “r” (with M-mode) vs. bunched or retroflex “r” ([ɻ])
- *r*-colored vowels
- clear/alveolar [l] vs. dark/velarized [ɫ]
- [n] vs. [ɺ] (cross-sectional view)
- Palatal segments vs. sequences of alveolar + palatal glide:
 - [ɲ] vs. [n+j] (*cañón* vs. *canyon*) (one gesture)
 - [ʎ] vs. [l+j] (*millón* vs. *million*) (one gesture)
 - also *eɫ yate*, *uɲ llorón* (where in Spanish the lateral or nasal anticipates the place of articulation of following palatal sound)
- alveolar vs. dental [t, d]
- Stops/occlusive/plosives vs. fricatives/spirants/approximants, e.g.,
 - [g] vs. [ɣ] (*gol* vs. *su gol*)
 - [k] vs. [x] (*acá* vs. *ajá*)
- sibilants ([s] with tongue tip up or down; cross-sectional view)

SAMPLE RESOURCES AND TOOLS

fMRI

The “span | speech production and articulation knowledge group” at the University of Southern California hosts the site at http://sail.usc.edu/span/rtmri_ipa/index.html. Here, there are a real-time MRI IPA charts with clickable IPA symbols that call up videos of both consonants and vowels, and by a variety of male and female speakers.

the rtMRI IPA chart (Pat Keating)

Click on any of the red-colored speech sounds or utterances below to see their production captured with real-time MRI. The videos comprise 83 frames per second. Each pixel corresponds to a square 2.4 mm wide. The data were collected in June 2015. The speaker is Professor Pat Keating (UCLA).

Click [here](#) for more versions of the rtMRI chart.

Consonants (Pulmonic)

	Bilabial	Labiodental	Dental	Alveolar	Postalveolar	Retroflex	Palatal	Velar	Uvular	Pharyngeal	Glottal
Plosive	p b			t d		ʈ ɖ	c ɟ	k ɡ	q ɢ		ʔ
Nasal	m	ɱ		n		ɳ	ɲ	ŋ	ɴ		
Trill	ʙ			ʀ					ʀ		
Tap or Flap		ɸ		ɾ		ɽ					
Fricative	ɸ β	f v	θ ð	s z	ʃ ʒ	ʂ ʐ	ç ʝ	x ɣ	x ɣ	ħ ʕ	h ɦ
Lateral fricative				ɬ ɮ							
Approximant		ʋ		ɹ		ɻ	j	ɰ			
Lateral approximant				l		ɭ	ʎ	ʟ			

Consonants (Non-Pulmonic)

Clicks

- ◌ Bilabial
- ◌ Dental
- ◌ (Post)alveolar
- ◌ Palatoalveolar
- ◌ Alveolar Lateral

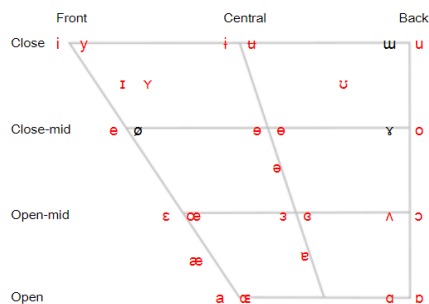
Voiced Implosives

- ◌ Bilabial
- ◌ Dental/Alveolar
- ◌ Palatal
- ◌ Velar
- ◌ Uvular

Ejectives

- ◌ Bilabial
- ◌ Dental/Alveolar
- ◌ Velar
- ◌ Alveolar Fricative

Vowels



Other Symbols

- ◌ Voiceless labial-velar fricative
- ◌ Voiced labial-velar approximant
- ◌ Voiced labial-palatal approximant
- ◌ Voiceless epiglottal fricative
- ◌ Voiced epiglottal fricative
- ◌ Epiglottal plosive
- ◌ Alveolo-palatal fricatives
- ◌ Voiced alveolar lateral flap
- ◌ Simultaneous ʃ and x
- ◌ Affricates
- ◌ (double articulation)

Words, Sentences and Passages

heed, hid, hayed, head, had, hod, howed, hood, hoed, who'd, hud, hide, how'd, hoy'd, hued
 bead, bid, bayed, bed, bad, bod, bawed, boud, bode, bood, bud, bide, bowed, Boyd, byued
 beet, bit, bait, bet, bat, pot, but, bought, boat, boot, put, bite, bird, abbot, bute

"She had your dark suit...", "Don't ask me to carry...", "The girl was thirsty...", "Your good pants..."
 Rainbow Passage, Grandfather Passage

Figure 2. “span | speech production and articulation knowledge group” sample real-time MRI IPA chart. Note: See Figure 3 for a video example.

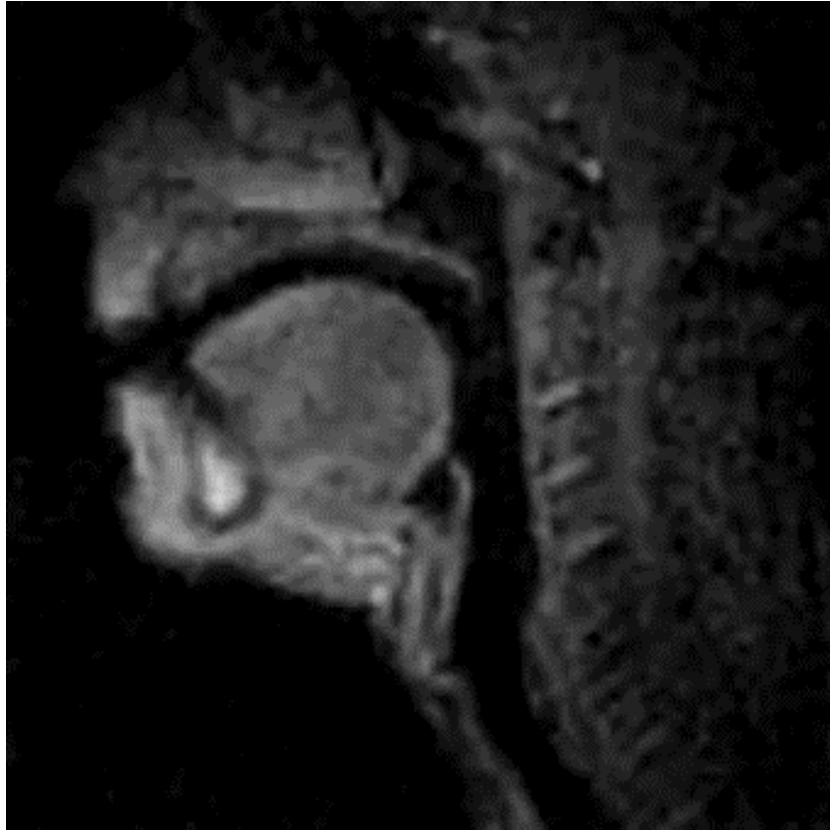

Figure 3. Sample sentence production.

http://sail.usc.edu/span/rtmri_ipa/videos/je_2015/the_girl_was_thirsty.html

Another excellent resource is the MRI capture of the lip-synch of pop singer Adele's song *Hello* by speech researcher Nadine Lavan of the Royal Holloway Vocal Communication Laboratory, University of London: <http://www.carolynmcgettigan.com/media>, image capture here (and also available on Facebook [here](#)):

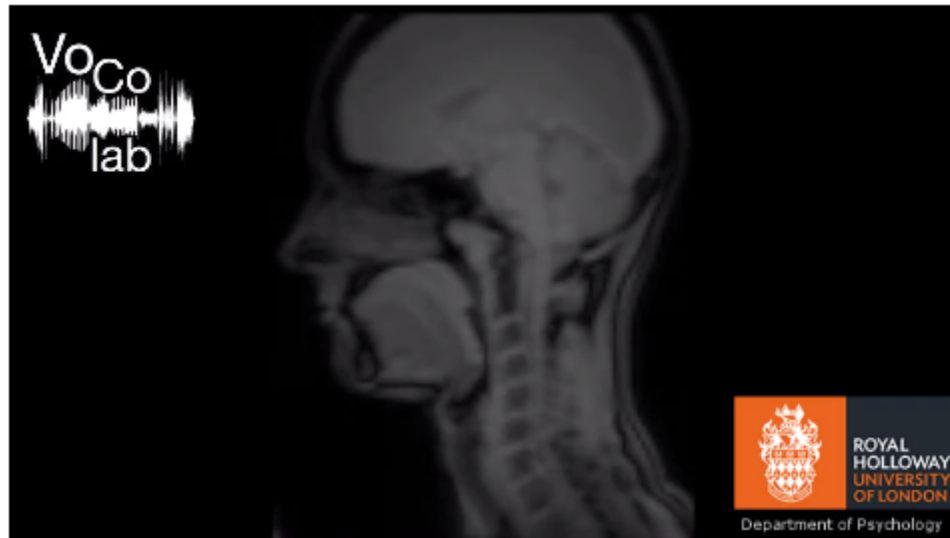


Figure 4. MRI capture of the lip-synch of Adele song *Hello*. Royal Holloway Vocal Communication Laboratory.

ULTRASOUND IMAGING

Two excellent resources are the websites “eNunciate!” and “Seeing Speech: IPA Charts.”

eNunciate! (<http://enunciate.arts.ubc.ca/>) is a visual language learning tool developed at the University of British Columbia with the aim of applying ultrasound technology to test biovisual feedback in the context of the language learning (Figure 5). It includes ultrasound overlay videos, in which ultrasound images of tongue movements in speech are superimposed on videos of a face to allow users to visualize how facial and tongue muscles are coordinated. (eNunciate! Homepage)

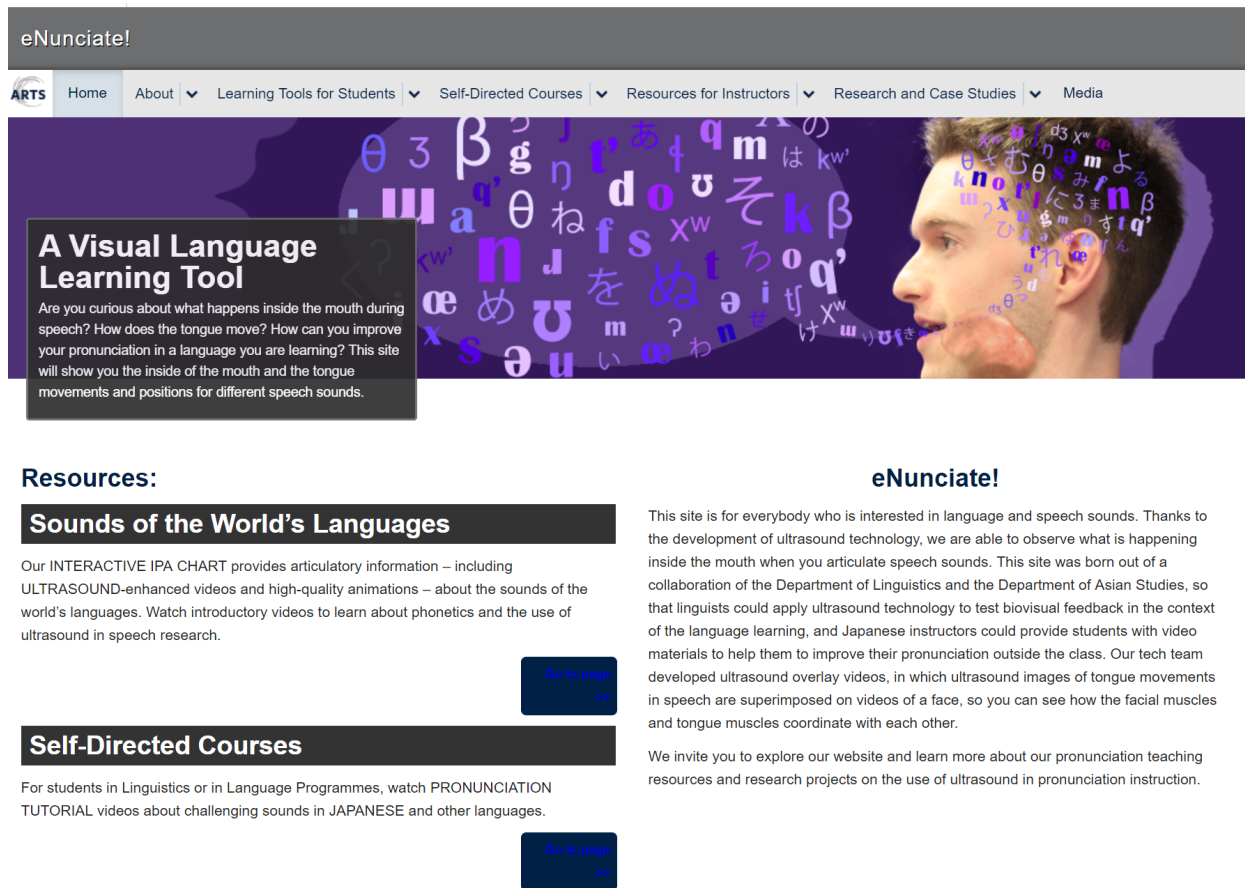


Figure 5. Screen shot of home page of eNunciate! Website.

For students, there are introductory videos as well as clickable IPA charts with real-time ultrasound imaging and with animations. See Figure 6 for sample consonant and vowel sounds.

Home / x

/x/ Voiceless Velar Fricative (Lower-case X)

← Go Back to Chart

Instructions:

Articulator: Back of the tongue (tongue dorsum)

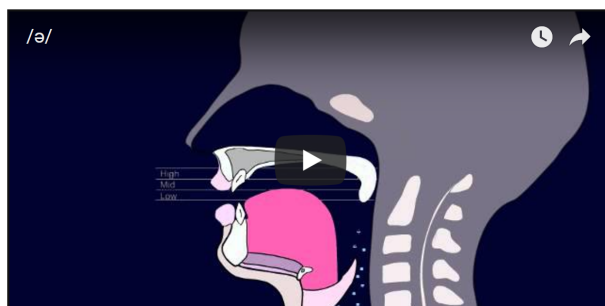
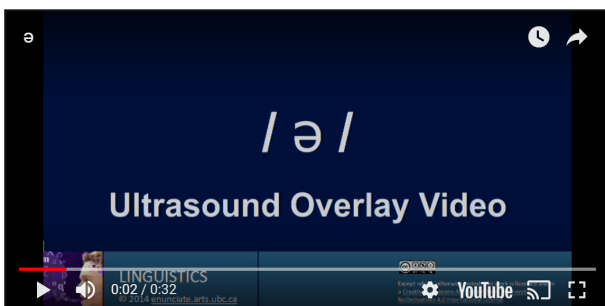
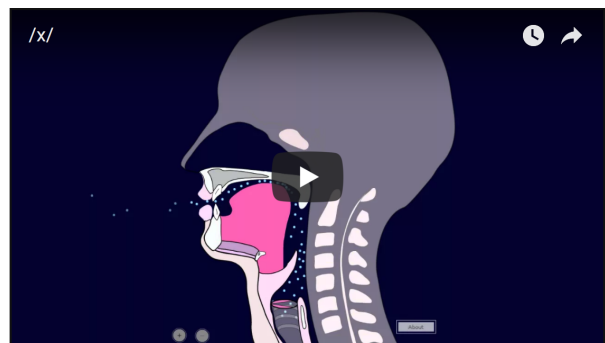
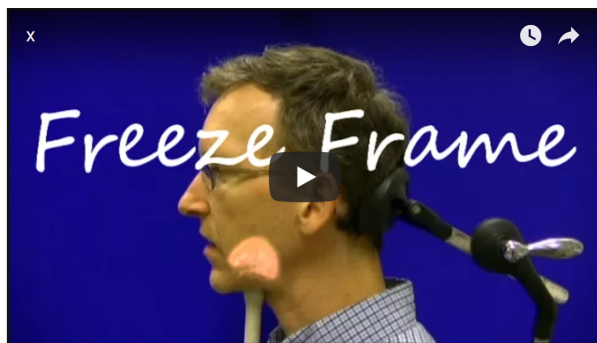Point of Articulation: Velum

Manner of Articulation: Fricative: The articulator makes a narrow constriction against the point of articulation, so when the airflow goes through the oral passage, audible friction noise is created.

Voice: voiceless – Vocal folds are apart and are not vibrating.

Occurrence:

Abaza, Adyge, Afrikaans (some speakers), Aleut (Atkan dialect), Arabic (Modern Standard), Assamese, Assyrian Neo-Aramaic, Avar, Azerbaijani, Basque (some speakers), Breton,



Source	Notes	URL
	Ultrasound	http://www.youtube.com/watch?v=kkOEKID3g7U
	Ultrasound	http://www.youtube.com/watch?v=mEG3BN46eE0
ArticulatoryIPA	– half-speed	http://www.youtube.com/watch?v=wLXiiWEL8Qs http://www.youtube.com/watch?v=BN3M6HEZOaQ
Ken Stevens (1962)	X-Ray	http://www.youtube.com/watch?v=DcNMCB-Gsn8&list=PLDC5CFA68CD4AD861#t=0m11s http://linguistics.berkeley.edu/acip/course/chapter3/x_ray.html
University of South California	MRI; with noise	http://sail.usc.edu/span/videos/dai.mov
SpeechTrainer.de (Youtube)	Animation	http://www.youtube.com/watch?v=XvFdN1_3Bn4

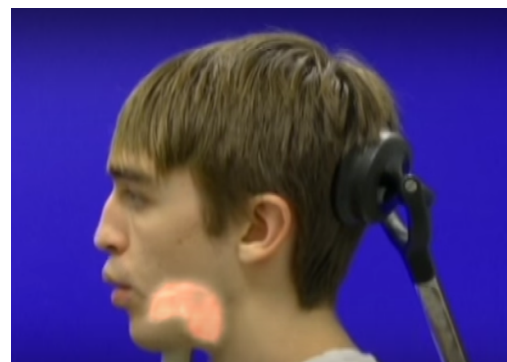

Figure 6. Screen shot of real-time ultrasound imaging and animations of sample consonant and vowel.

There are Self-Directed Courses with tutorial videos about challenging sounds in Japanese and Cantonese with other languages still under development; additional tools like a Prosody Analyzer are likewise under development. For language instructors, there is also the Tongue Visualizer kit with which to produce custom resources that target language-specific pronunciation challenges. (eNunciate! Tongue Visualizer)

Seeing Speech (<http://www.seeingspeech.ac.uk/>), developed by phoneticians at the University of Glasgow, is another articulatory web resource for the study of phonetics, and includes MRI, ultrasound and animations (Figure 7). It provides clickable IPA charts (<http://www.seeingspeech.ac.uk/ipachart/>) with multiple visualizations by male and female talkers, and users can select by consonants or vowels; by MRI, ultrasound or animation; and by talker (not all sounds and tools available for both talkers).

The International Phonetic Alphabet (revised to 2005)

Consonants (Pulmonic) MRI Janet Beck Missing some symbols? Apply Doulos SIL font

Consonants (Pulmonic)

	Bilabial	Labiodental	Dental	Alveolar	Postalveolar	Retroflex	Palatal	Velar	Uvular	Pharyngeal	Glottal
Plosive	p b			t d		ʈ ɖ	c ɟ	k ɡ	q ɢ		ʔ
Nasal	m	ɱ		n		ɳ	ɲ	ŋ	ɴ		
Trill	ʙ			r					ʀ		
Tap or Flap		ɸ		ɾ		ɽ					
Fricative	ɸ β	f v	θ ð	s z	ʃ ʒ	ʂ ʐ	ç ʝ	x ɣ	χ ʁ	ħ ʕ	h ɦ
Lateral fricative				ɬ ɮ							
Approximant		ʋ		ɹ		ɻ	j	ɰ			
Lateral approximant				l		ɭ	ʎ	ʟ			

Figure 7. Screen shot of Seeing Speech’s IPA clickable chart.

An additional resource linked to this site is **Dynamic Dialects** (<http://www.dynamicdialects.ac.uk/>), which contains a clickable world map and well as a clickable table (<http://www.dynamicdialects.ac.uk/accntchart/accntchart.php>) of speakers of different dialects producing a variety of words as well as extended spontaneous speech (last column of chart). Ultrasound tongue imaging of real-time captures is accompanied by inset videos of front and side views of the selected articulation.

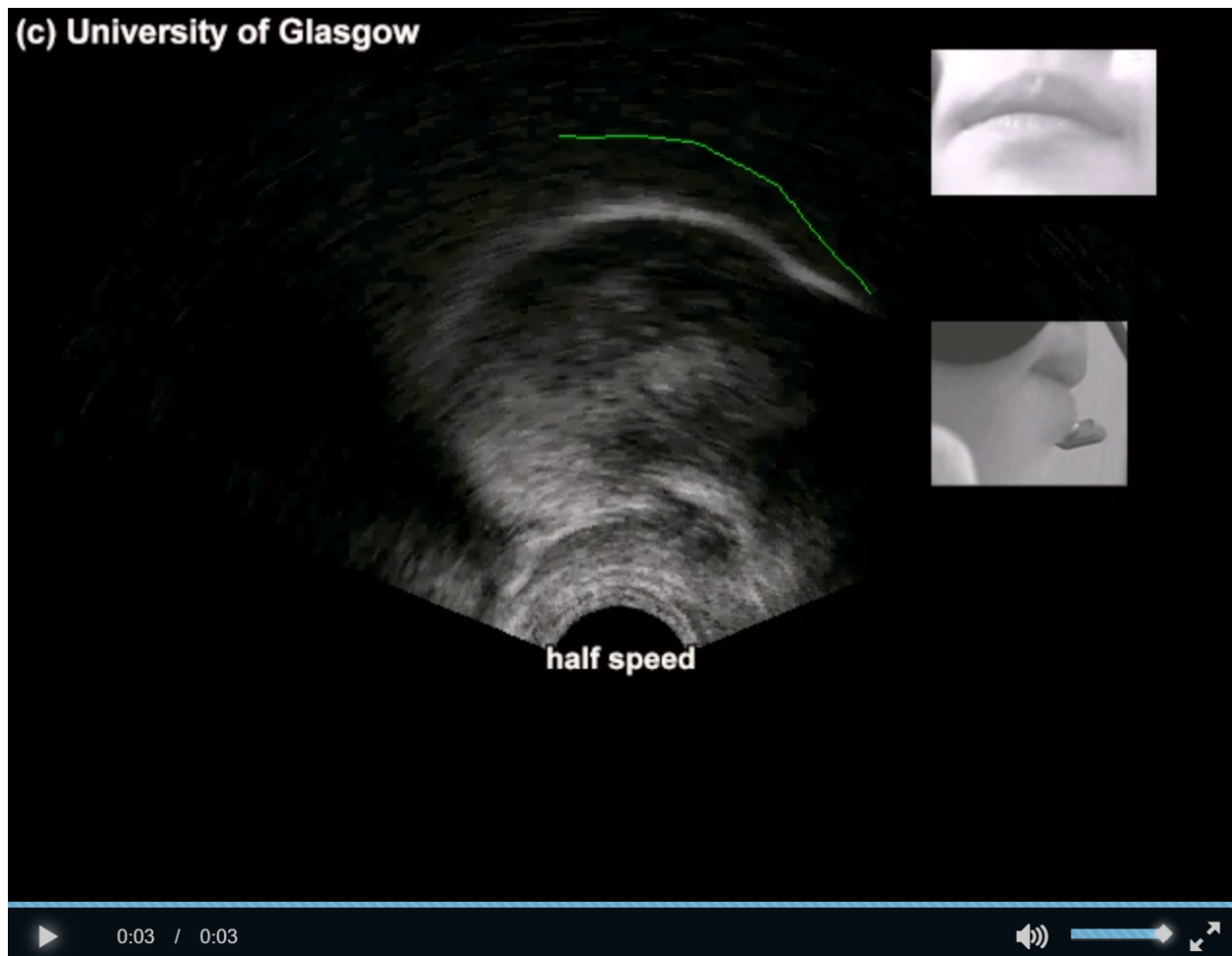

Figure 8. Screen shot of female talker from Georgia pronouncing *lot* from Seeing Speech's Dynamic Dialects clickable chart.

CONCLUSION

Real-time visualizations of the articulation of speech are invaluable to improve understanding of the fine-grained mechanisms of speech production of one's native language, and they are very helpful in the learning of and practice with the pronunciation of non-native sounds and sequences. There are excellent online resources with MRI, ultrasound and animation imaging, and the availability and relative affordability of portable ultrasound devices further allows students and instructors to facilitate the development of the proprioception of different and challenging articulatory features as speakers develop their mastery of second language phonology.

ABOUT THE AUTHOR

D. Eric Holt is Associate Professor of Spanish and Linguistics in the Department of Languages, Literatures, and Cultures and the Linguistics Program at the University of South Carolina. His

scholarly interests include Hispanic linguistics, historical phonology, dialectology and phonological theory, as well as second language phonology, particularly of connected speech.

Department of Languages, Literatures, and Cultures, and Linguistics Program, University of South Carolina, 1620 College Street, Columbia, SC 29208, (803) 777-2063, deholt01@mailbox.sc.edu.

SELECTED ONLINE RESOURCES

<http://enunciate.arts.ubc.ca/>. eNunciate! University of British Columbia. (Ultrasound with Tongue Visualizer)

Research by the eNunciate Team listed at <http://enunciate.arts.ubc.ca/research-and-case-studies/team-research/>

Bird, S., H. Bliss, and B. Gick. (2017). Visualizing Speech in a Classroom Setting Using Interactive Ultrasound Imaging. 60-minute workshop presented at the [2017 PSLLT Research Methods Workshop](#). Salt Lake City, University of Utah: August 31, 2017. [[slides](#)] (this PSLLT conference pre-conference workshop)

http://sail.usc.edu/span/rtmri_ipa/index.html (MRI)

real-time MRI IPA charts. span | speech production and articulation knowledge group

<http://www.seeingspeech.ac.uk/ipachart/> (MRI, ultrasound, animation)

Lawson, E., Stuart-Smith, J., Scobbie, J. M., Nakai, S., Beavan, D., Edmonds, F., Edmonds, I., Turk, A., Timmins, C., Beck, J., Esling, J., Leplatre, G., Cowen S., Barras, W., Durham, M. (2015). Seeing Speech: an articulatory web resource for the study of Phonetics. University of Glasgow. 1st April 2015. <http://www.seeingspeech.ac.uk/>

REFERENCES

- Adler-Bock, M. (2004). *Visual feedback from ultrasound in remediation of persistent /r/ errors: Case studies of two adolescents*. MS thesis, University of British Columbia.
- Adler-Bock, M., Bernhardt, B. M., Gick, B., & Bacsfalvi, P. (2007). The use of ultrasound in remediation of North American English/r/in 2 adolescents. *American Journal of Speech-Language Pathology*, 16(2), 128-139.
- Bernhardt, B., et al. (2005). Ultrasound in speech therapy with adolescents and adults. *Clinical Linguistics & Phonetics* 19(6-7), 605-617.
- Bernhardt, B., Bacsfalvi, P., Gick, B., Radanov, B., & Williams, R. (2005). Exploring electropalatography and ultrasound in speech habilitation. *Journal of Speech-Language Pathology and Audiology* 29, 169-182.
- Bernhardt, B., Gick, B., Bacsfalvi, P., & Ashdown, J. (2003). Speech habituation of hard of hearing adolescents using electropalatography and ultrasound as evaluated by trained listeners. *Clinical Linguistics and Phonetics* 17, 199-216.
- Birdsong, D. (2007). Nativelike pronunciation among late learners of French as a second language. In M. J. Munro & O.-S. Bohn (Eds.), *Second language speech learning: The*

- role of language experience in speech perception and production*. Amsterdam: John Benjamins.
- Campbell, F. M. (2004). *The gestural organization of North American English /r/: A study of timing and magnitude*. MA Thesis, University of British Columbia.
- de Bot, C. L. J. (1980). The role of feedback and feedforward in the teaching of pronunciation. *System*, 8, 35-45.
- Gick, B., Allen, B. & Stavness, I. (2017). Speaking tongues are actively braced. *Journal of Speech, Language and Hearing Research*, 60(3), 494-506.
- Gick, B., Bernhardt, B., Bacsfalvi, P., & Wilson, I. (2008). Ultrasound imaging applications in second language acquisition. In J. Hansen & M. Zampini (Eds.), *Issues in Second Language Phonology*. Cambridge, U.K.: Cambridge University Press.
- Gick, B., Wilson, I., Koch, K., & Cook, C. (2004). Language-specific articulatory settings: Evidence from inter-utterance rest position. *Phonetica* 61, 220–233.
- Kelsey, C. A., Woodhouse, R. J., & Minifie, F. D. (1969). Ultrasonic observations of coarticulation in the pharynx. *Journal of the Acoustical Society of America* 46, 1016–1018.
- MacKay, I. R. A. (1977). Tenseness in vowels: An ultrasonic study. *Phonetica*, 34, 325–351.
- Sonies, B. C., Shawker, T. H., Hall, T. E., Gerber, L. H., and Leighton, S. B. (1981). Ultrasonic visualization of tongue motion during speech. *Journal of the Acoustical Society of America* 70, 683–686.
- Neri, A., Cucchiari, C., Strik, H., & Boves, L. (2002). The pedagogy-technology interface in computer assisted pronunciation training. *Computer Assisted Language Learning*, 15(5), 441-467.
- Pillot-Loiseau, C., Kamiyama, T., & Antolik, T. K. (2015). French /y/-/u/ contrast in Japanese learners with/without ultrasound feedback: Vowels, non-words and words. In *International Congress of Phonetic Sciences (ICPhS)* (pp. 1-5). International Phonetic Association: London.
- Wilson, I. (2003). An ultrasound study of articulatory tongue gestures in bilingual Japanese-English children's speech. Paper presented at the 4th International Symposium on Bilingualism (ISB4), Arizona State University, Tempe, AZ.
- Wilson, I., & Gick, B. (2006). Ultrasound Technology and Second Language Acquisition Research. In *Proceedings of the 8th Generative Approaches to Second Language Acquisition Conference (GASLA 2006)*, ed. Mary Grantham O'Brien, Christine Shea, and John Archibald, (pp.148-152). Somerville, MA: Cascadilla Proceedings Project. <http://www.lingref.com/cpp/gasla/8/paper1497.pdf>